

## Migraine and temporomandibular disorder triggered by stress-induced bruxism: a case report

Migrain dan gangguan temporomandibular yang dipicu oleh bruxism yang diinduksi stres: laporan kasus

Astari Larasati, Pinta Marito, Laura Susanti Himawan, Ira Tanti

Prosthodontic Department

Faculty of Dentistry Universitas Indonesia

Jakarta, Indonesia

Corresponding author: **Ira Tanti**, e-mail: [iratanti@gmail.com](mailto:iratanti@gmail.com)

### ABSTRACT

Migraine is the most common primary headache that associated with temporomandibular disorders (TMD) that is known as number of clinical problems involving the masticatory muscles, temporomandibular joint and associated structures. Bruxism may be considered as an important factor of initiation of TMD and stress might be the contributory factor. This article is aimed to discuss the management of migraine and TMD patient with stress-induced bruxism as a precipitating factor. A 42-year-old male patient visited RSKGM FKGUI due to throbbing pain, headache and discomfort around ear and face. Patient was diagnosed myalgia based on DC/TMD with no articular joint disorder and migraine according to orofacial pain classification axis-1 following with anxiety disorder and stress. A stabilization appliance was designed followed with patient education, physical therapy and stress management. It was concluded that treatment combination of stabilization appliance, stress management and significantly improve the patient's condition with lessen migraine attack and TMD symptoms.

**Keywords:** temporomandibular disorder, migraine, stress, bruxism, stabilization appliance

### ABSTRAK

Migrain merupakan nyeri kepala primer yang paling sering dikaitkan dengan gangguan sendi temporomandibula (GSTM), yaitu sekumpulan masalah klinis yang melibatkan otot pengunyahan, sendi temporomandibula dan struktur terkait di sekitarnya. *Bruxism* dianggap sebagai faktor penting yang menginisiasi terjadinya GSTM dan stres mungkin menjadi faktor penyebabnya. Artikel ini membahas tatalaksana pasien migrain dan GSTM dengan *bruxism* akibat stres sebagai faktor pencetusnya. Seorang laki-laki berusia 42 tahun datang ke RSKGM FKGUI karena nyeri berdenyut, sakit kepala dan rasa tidak nyaman di sekitar telinga dan wajah sebelah kiri. Pasien didiagnosis *myalgia* berdasarkan DC/TMD tanpa gangguan sendi dan migrain menurut klasifikasi nyeri orofasial axis-1 diikuti dengan gangguan kecemasan dan stres. Dilakukan terapi definitif berupa pembuatan *stabilization appliance* dan terapi suportif berupa edukasi pasien, latihan rahang dan manajemen stres. Disimpulkan bahwa kombinasi terapi definitif dan suportif secara signifikan meningkatkan kondisi pasien dengan mengurangi serangan migrain dan gejala GSTM.

**Kata kunci:** gangguan sendi temporomandibula, migrain, stres, *bruxism*, *stabilization appliance*

Received: 10 September 2022

Accepted: 12 October 2022

Published: 1 December 2022

### INTRODUCTION

According to the second edition of The International Classification of Headache Disorder, migraine is classified into primary headache.<sup>1</sup> Migraine is a headache that often affects one side of the head and can be extremely painful, throbbing, or pulsating. It frequently comes with high sensitivity to light and sound as well as nausea and vomiting. The pain from a migraine attack can be so intense that it interferes to do regular activities, lasting anywhere from hours to days.<sup>1</sup> The characteristic of a migraine is throbbing, moderate to severe, and sometimes paralyzing pain. Migraine is a severe type of headache that affect 16% of population.<sup>1</sup> Complex factors, including genetic and psychological factors together with environmental influences, can cause migraines. Stress has been identified as one of the components influencing the prevalence of migraines.<sup>2</sup> This is consistent with previous findings reported by WHO in 2016, stated that anxiety and depression are associated to migraine.

Temporomandibular disorders (TMD) is a common term used to describe disorders related to masticatory muscles, temporomandibular joint (TMJ), and the associated structure.<sup>3</sup> The global prevalence of TMD ranges 21.5-51.8%, with female: male ratio of 2:1.<sup>2</sup> It is generally accepted that TMD has a complex and multifactorial etiology due to several factor could contribute to this disorders such as occlusal condition of the teeth, trauma, deep pain input, parafunctional activity, hormones, psychological distress and others.<sup>4</sup> Asymmetric mandibular motions, restricted mouth opening, muscle and TMJ pain, joint sound, and muscle sensitivity through palpation are some of the most typical TMD signs and symptoms.<sup>4</sup> TMD and primary headaches can be perpetual and debilitating musculoskeletal and neurological disorders. The presence of both can affect up to one-sixth of the population at any one time.<sup>5</sup> TMDs were initially believed to be primarily musculoskeletal conditions, whereas migraine was believed to be purely a cerebral condition.<sup>5</sup> There is a correlation

between TMD and headache. Patients experiencing headaches are more likely to experience TMD symptoms and signs.<sup>6</sup> Recent investigations have shown a more specific link between TMD and primary headaches, demonstrating that they are two distinct conditions that interact to cause and aggravate each other. Migraine was the most common primary headache diagnosis in individual with TMD.<sup>2</sup> In addition, headache and sleep bruxism or other parafunctional habits seems to be associated.<sup>6</sup>

Bruxism is a repetitive muscular activity of the jaw characterized by grinding and clenching the teeth and bracing or thrusting the mandible, is mainly regulated centrally, and may involve more than dental contact.<sup>7</sup> Currently, bruxism has a distinction between sleep bruxism and awake bruxism. Sleep bruxism is a masticatory muscle activity during sleep that is characterized as rhythmic (phasic) and non-rhythmic (tonic) and is not a movement disorder or a sleep disorder in otherwise healthy individuals, whilst, awake bruxism is a masticatory muscle activity during wakefulness that is characterized by repetitive or sustained tooth contact and/or by bracing or thrusting of the mandible and is not a movement disorder in otherwise healthy individuals.<sup>7</sup> Sleep bruxism is the most common oral parafunction activity with a prevalence of up to 90% in general population.<sup>8</sup> In the general adult population, the prevalence based on the self-reporting of clenching of the teeth during waking hours is about 20%.<sup>9</sup> Researchers have been working to identify the risk factors for sleep bruxism and its correlation with other dental or medical diseases. Several factors are already associated with sleep bruxism, including gastroesophageal reflux disease, genetic factors, tinnitus, TMD, chronic migraine, and nicotine or alcohol consumption, poor sleep quality and personality traits, such as stress, have also been associated with sleep bruxism.<sup>6</sup> Sleep bruxism may be considered an important factor of initiation and perpetuation of TMD pain.<sup>10</sup>

The psychological factors that are known to be associated with bruxism and TMD are stress and anxiety.<sup>8</sup> According to WHO page, stress can be defined as any type of change that causes physical, emotional or psychological strain. Stress is body's response to anything that requires attention or action. Everyone experiences stress to some degree. The way to respond to stress, however, make a big difference to your overall well-being. Stress can manifest as fear, worry, anxiety, inability to relax, increased heart rate, difficulty in breathing, disturbance in sleeping patterns, change in eating patterns, difficulty in concentrating worsening of pre-existing health conditions, physical and mental, and increased use of alcohol, tobacco and other drugs.<sup>11</sup> Studies have discovered relationships between bruxism and

stress, finding that people with high levels of sleep bruxism activity report more anxious at work and in life.<sup>8</sup>

This case report reported the case of a patient who experienced migraine and was diagnosed with TMD with bruxism and stress as contributing factors treated with stabilization appliance made of hard acrylic resin.

## CASE

A 42-year-old male patient came to RSKGM FKG UI on June 2022 due to throbbing pain, headache and discomfort around ear and face. Pain is felt on the left side of the head and face. Patient feels discomfort and it spreads to the ear. When the patient was busy and under stress, this headache occurred practically every day and grew worse. The pain emerged initially on June 2021 when woke up in the morning. It was felt on the left side and getting worse when eating and talking. Whenever the headache occurred patient also experience an extreme acoustic sensitivity, especially when hearing loud stimuli like car horns or loud noises at public place. He also reported that there is a clicking sound when the mouth is opened widely or eating and have tinnitus, although the volume has recently decreased.

On July 2021, patient visited an ear nose throat (ENT) specialist to consult his complaints. Audiometry, tympanometry and loudness discomfort test were carried out and no ear infections and abnormalities were found. The ENT specialist then referred the patient to neurologist. During this period patient went to a dentist and was told that he might had a TMD but because he still thought the issue was with the ear, treatment was not administered. December 2021, patient visited a neurologist, MRI and specific nerve tasting: a sense of touch and a sense of pain were carried out and there were no abnormalities found. He consulted with a neurosurgeon during this period, and the neurosurgeon advised prioritizing the treatment of TMD issues first because TMD can also contribute to complex pain on the side of the face. There were also some medications prescribed by the ENT specialist, neurologist and neurosurgeon such as Betaserc 24, sancoidan, analcic, mecobalamine, cerini and carbamazepine.

Patient visited prosthodontist in RSCM Jakarta for a consultation on January 2022. A soft splint nightguard was designed after the patient underwent examinations and was diagnosed with TMD. It was also known that the patient had a habit of bruxism when asleep. After 6 months, there had been slightly improvement of healing, pain in the left side of the head and in area surrounding the ear were still existed and it really bothered him.

Patient decided to come to RSKGM FKG UI because the pain was getting intense. Extraoral, intraoral and radiology examinations were then carried out. An extraoral photo documentation was also taken (Fig. 1).

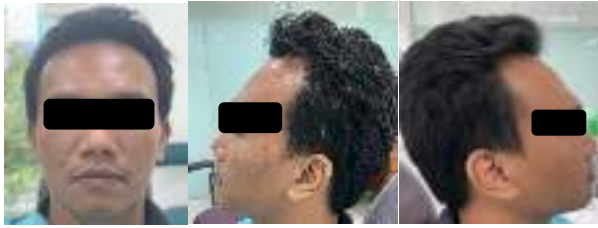

Figure 1 Extraoral photo

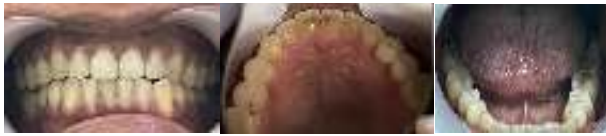

Figure 2 Intraoral photo

According to Axis-1 DC/TMD clinical examination, patient's overbite 2 mm and overjet 3 mm (Fig.2). There was also 2 mm corrected deviation to the right-side during mouth opening. Pain was detected in the palpation of left and right masseter muscle, left anterior temporalis muscle, left submandibular region, left sternocleidomastoideus muscle and left lateral pterygoid muscle. No clicking sound was found during examination. Clicking usually found after eating. Functional manipulation test was performed and there was pain on the left joint. There was no restriction in mouth opening. Pain free mouth opening 45 cm, maximum unassisted opening 50 cm and maximum assisted opening 51 cm. Left lateral movement 6 cm with discomfort and tension in temporalis area and right lateral movement 7 mm. Protrusive movement 8 cm with discomfort and tension felt around temporalis area.

Conclusions drawn from Axis-2 examinations, pain drawing examination category was severe since patient was able to identify 4 body areas with pain, *graded chronic pain scale category* was severe, *chronic pain grade category* was moderately limiting, and *oral behavioral checklist* (parafunction) category was high. Patient's score on PHQ-9 and GAD-7 as depression and anxiety examination were severe and moderate. From this examination it is known that patient had bruxism when sleeping and also clenching during the day especially when concentration and working with computer.

Panoramic and TMJ x-ray were also carried out in the first visit. Teeth 17 and 46 were missing and according to the TMJ x-ray, there was increasing condylar mobility during mouth opening (Fig.3-4).

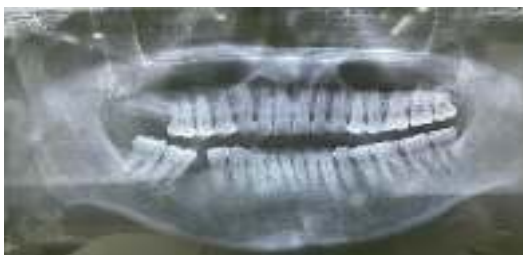

Figure 3 Panoramic x-ray

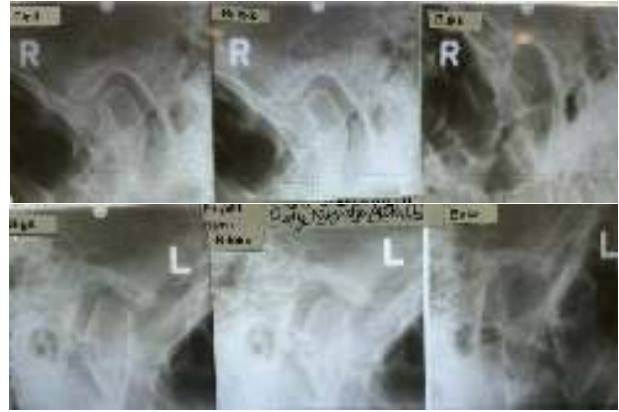

Figure 4 TMJ X-ray; R = right, L = left

Following a thorough examination, patient was diagnosed myalgia based on DC/TMD diagnostic tree with no articular joint disorder. Patient was also diagnosed migraine according to orofacial pain classification axis-1 following with anxiety disorder and stress. Patient was told to reduce his clenching habit during concentration and working, self-regulation to minimize stress. Patient were taught to do jaw regular jaw exercise 3-4 times a day with eight times repetitions such as opening mouth in front of the mirror in straight pathway, opening the mouth without pain, and lateral movement with restriction. Alginate impression and bite registration using bitewax were taken for the making of SA. Next visit was scheduled 2 weeks later.

At SA delivery appointment, patient still felt the throbbing pain on the left side of the face quiet often. No restriction in mouth opening. Patient felt discomfort and tension around the face in masseter and temporalis muscle area after woke up in the morning. Pain was felt in the palpation of masseter, temporalis, pterygoid lateralis, left sternocleidomastoideus muscle and left submandibular regio. The SA was inserted and some adjustment was done during the insertion. Occlusion and articulation adjustment were performed until simultaneous occlusion and articulation obtained. Regular jaw exercise was still suggested to the patient and evaluation visit was scheduled a week after the insertion (Fig.5A).

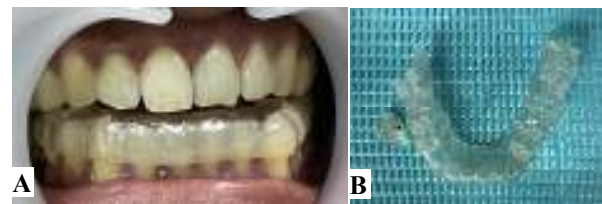


Figure 5A Stabilization insertion; B chipped SA

1<sup>st</sup> Post delivery visit evaluation, patient still felt tension and discomfort on the area around the head when speaking for a long time at a meeting or conversing and when waking up, but the severity lessens (in 7 days there are 3 times the tension when waking up). Mi-

graine happened only once or twice a week. Jaw exercise was still suggested to the patient. Next visit was scheduled a month after.

At 2<sup>nd</sup> post delivery visit evaluation, patient felt significant improvement, the pain was significantly diminished. No more pain in temporalis area, masseter and sternocleidomastoideus muscle during palpation. Migraine only happens one time from the last visit. Patient managed to control his clenching habit at day-time but unable to manage his sleep bruxism habit. At this visit patient reported that the SA was chipped in the right second molar area so he intended to fix it (Fig.5B). The SA was then fix chairside using self-curing acrylic (Fig.6). Patient was instructed to continue the jaw exercise and scheduled once a month visit for the next 6 months.

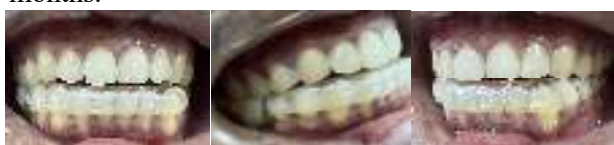

Figure 6 Repaired stabilization appliance

## DISCUSSION

In this case report patient experienced a very intense throbbing pain in left side of the head and face followed with extreme acoustic sensitivity, especially when hearing loud stimuli or loud noises. This pain limiting patient from doing regular activities since any physical activities even simple head movement could aggravate the pain. This is a characteristic of migraine as a primary headache.<sup>12</sup> According to DC/TMD examinations patient was diagnosed as myalgia with no articular joint disorder. Research found that there is significant relationship between headache and TMD.<sup>6</sup> TMD are comorbid with headache and non specific activation of common central nervous system pathways (e.g. trigeminal nucleus caudalis) explain the comorbidity, which would be, therefore, bidirectional (pain in the trigeminal distribution predisposes to other forms of facial pain or headache).<sup>6</sup> This fact has pathophysiological and therapeutic importance as one (e.g. TMD) may contribute to refractoriness to treatment of the second (e.g. migraine).<sup>6</sup> Other study also stated that headache is more likely to be in myogenous TMD rather than arthrogeous TMD.<sup>5</sup> Considering the presence of TMD in the various types of primary headache, migraine was most common and TMD alone was associated with significant risk of chronic migraine.<sup>5</sup> TMD and migraines can both cause significant amounts of pain and since TMD and migraines both involve the trigeminal nerve and share a number of similar symptoms, many patients who actually have TMD are misdiagnosed as having migraines only instead. Patients who have been misdiagnosed may be resistant to traditional migraine treatments. Therefore, a patient experiencing TMD may

continue to suffer from these episodes of pain because they have been misdiagnosed as having migraines only whilst the other factor contributing the TMD are not found and being control. Hence, a comprehensive and thorough examinations must be carried out so that the proper treatment could be administered for the patient.

Axis-II examinations showed that patient has parafunctional habit such as clenching and bruxism at night. This habit increase the masticatory muscles activity and may lead to negative oral health consequences for example severe masticatory muscle pain, TMJ pain either myogenous or arthrogeous, and extreme tooth wear.<sup>7</sup> Fernandes et al reported a study showed the prevalence of sleep bruxism was higher among individuals with headache. In a group of individuals with chronic migraine, 74,6% presented with sleep bruxism and the association was significant.<sup>6</sup> The correlation between painful TMD and headache diagnoses was also significant in patients with sleep bruxism. It has been reported that patient with sleep bruxism and TMD are more likely to present with headaches and complaints of tightness in frontotemporal area. It was also found that sleep bruxism alone did not increase the risk for any primary headaches but when associated with TMD the odds were significantly increased.<sup>6</sup>

In this case, stress has been associated with the occurrence of bruxism. This assumption was based on patient's score on PHQ-9 and GAD-7 as depression and anxiety examination were severe and moderate. Patient also noticed his psychocological condition and it was caused by occupational exposure tension, achievement situations claiming goal-directed performance and anxiety. Bruxism functions as a kind of perpetual motion machine, as intensifying symptoms resulting from an organism's abnormal functioning increase a feeling of being stressed and in consequence lead to an increased muscle tone and teeth grinding.<sup>7</sup> It is widely acknowledged that stressful situations and mental illnesses contribute to the emergence of parafunctional habits and TMD without being the only cause.

For effective treatment of TMDs and headaches an accurate diagnosis of both disorders is required. Primary headache disorders (e.g. migraine) have the ability to cause pain in the TMJ and associated structures whereas TMDs may have an associated headache or aggravated a primary headache.<sup>5</sup> Nevertheless, treatment results could potentially be enhanced by managing both disorders, the best results are often achieved by reducing as many predisposing, causative and perpetuating factors as possible. In this case, patient was prescribed with some medicines from previous doctors but that was not made him feeling better. The medicine was only working for several hours and after that the pain was still bothering him. This is because the main

precipitating factor was not eliminated or controlled. A SA from hard acrylic resin was then designed and made for the patient. This SA commonly used to relax jaw muscles, prevent TMJ trauma, protect dentition, possible reduction of masticatory muscle activity during sleep and control headaches. When looking at the use of SA in headache, an uncontrolled study found that 64% of patient had decrease in headache frequency and 30% showed complete remission of headache at 4 weeks.<sup>5</sup> This appliances should incorporate neurophysiologic and musculoskeletal principles to ensure that the appliance functions as intended, in this case to control the clenching and bruxism habits, treatment of the TMD and control the headache. Generally based on the materials, SA divided into hard and soft acrylic. Friction et al found a good evidence that single arch, hard, full coverage SA when adjusted properly had modest efficacy in the treatment of TMD pain and reducing bruxism habit.<sup>5</sup> Some studies indicate that soft splint material may actually increase bruxism activity in some patients.<sup>13</sup>

Patient education was also given as an essential part of the treatment. Patient was informed to avoid clenching during the day and bruxism at night by wearing the stabilization appliance. Patient was also informed that teeth do not touch except during chewing, swallowing or speech. During all other times, jaws should be positioned with teeth apart. Teeth should not be loaded more than 20 minutes in 24 hours other that, may in-

crease a negative risk of oral health consequences. Once the patient becomes aware of tooth contacts, then make a conscious effort to keep the teeth apart during all waking moments.

Physical therapy such as thermotherapy also recommended to the patient. A warm towel applied in symptomatics muscles area have been shown to reduce pain and improve function. Patient also taught to do regular jaw exercise with 8 times repetition for each motion and to be done 3 times a day. The regular jaw exercise recommended are standard jaw exercise and resistance movement exercise.

Emotional stress therapy was also suggested to the patient as stress was suspected to be the perpetuating factors in this case. Physical self-regulation was taught to the patient to help patient relaxed such as how to do diaphragmatic breathing, taking a brief-relaxation breaks, and begin to sleep earlier. After all the treatment was administered, significant improvement of the TMDs and migraine frequency is lessening.

It was concluded that a thorough examinations must be carried out in treating patient with migraine and TMD so that the aggravating factors could be identified and minimized. In this case, by asking the patient to relieve emotional stress and the use of stabilization appliance during sleeping showed a significant improvement in lessen the frequency of migraine and the TMD symptoms.

## REFERENCES

- Okeson JP. Bell's oral and facial pain. 7<sup>th</sup> Ed. Illinois: Quintessence Publishing Co, Inc; 2014.
- Ashraf J, Zaproudina N, Suominen A, Sipilä K, Närhi M, Saxlin T. Association between temporomandibular disorders pain and migraine: results of the health 2000 survey. *J Oral Facial Pain Headache* 2019;39(4):399-407. doi:10.11607/ofph.2213
- Putri MF, Kusdhany LS, Tanti I. Diagnostic indices for temporomandibular disorders (TMD): a systematic review. *J Int Dent Med Res* 2021;14(3):1160-8.
- Okeson JP. Management of temporomandibular disorders and occlusion. 8<sup>th</sup> Ed. Kentucky: Elsevier Inc.; 2020.
- Graff-Radford SB, Abbot JJ. Temporomandibular disorders and headache. *J Oral Maxillofac Surg* 2016;28:335-49.
- Fernandes G, Franco AL, Aparecida DDG, Speciali JG, Bigal ME, Camparis CM. Temporomandibular disorders, sleep bruxism and primary headaches are mutually associated. *J Orofac Pain* 2013;27(1):14-20.
- Lobbezoo F, Ahlberg J, Raphael KG. International consensus on the assessment of bruxism: Report of a work in progress. *J Oral Rehabil* 2018;45(11):837-44. doi:10.1111/joor.12663
- Ostrc T, Frankovič S, Pirtošek Z, Rener-Sitar K. Headache because of problems with teeth, mouth, jaws, or dentures in chronic temporomandibular disorder patients: a case-control study. *Int J Environ Res Publ Health* 2022;19(5). doi:10.3390/ijerph19053052
- Chemelo V dos S, Né YG de S, Frazão DR. Is there association between stress and bruxism? A systematic review and meta-analysis. *Front Neurol* 2020;11. doi:10.3389/fneur.2020.590779
- Alkudhairy MW. A Self reported association between temporomandibular joint disorder, headaches and stress. *J Int Soc Prev Comm Dent* 2018;8(4):371-80.
- Ohlmann B, Bomicke W, Habibi Y, Rammelsberg P, Schmitter M. Are there associations between sleep bruxism, chronic stress, and sleep quality? *J Dent* 2018;74:101-6.
- Burch RC, Loder S, Smitherman TA. The prevalence and burden of migraine and severe headache in the United States: updated statistics from government health surveillance studies. *J Head Face Pain* 2015;55(1):21-34.
- Ommernborn MA, Taghavi J, Singh P, Handschel J, Depprich RA. Therapies most frequently used for the management of bruxism by a sample of German dentists. *J Prosthet Dent* 2011;105(3):194-202.